

This Quick Reference Guide is designed to provide the CT Radiologist with rapid access to important information regarding NobelGuide™.

Please refer to the NobelGuide™ Procedures and Product Concept Manual for more detailed information.

NobelGuide™ represents an innovative new approach to implant placement. For the patient, NobelGuide™ provides maximum comfort by enabling minimally invasive procedures, thereby reducing discomfort, swelling and healing time. All while dramatically reducing the number of appointments required.

With Teeth-in-an-Hour™, the patient can return home on the day of surgery with their permanent prosthesis in place!

For the Dental Professional, NobelGuide™ provides increased predictability and safety, the ability to deliver the final prosthesis at the time of surgery (Teeth-in-an-Hour™) in as little as one appointment.

For the Radiology Laboratory, NobelGuide™ represents a new revenue stream that leverages the skills and equipment already in place while putting you at the leading edge of dental restoration technology.

In computer-based NobelGuide™ cases, CT scan data is used as a basis for surgical planning and for the production of a Surgical Template that guides the surgery during installation of dental implants. It is, therefore, important that the CT scan data is a true representation of the dental anatomy of the patient.

Generic CT Protocol

Single Slice CT Scanner

Scan Settings

- Spiral CT
- No gantry tilt
- Tube voltage: 120 kV
- Effective tube current: 100 mAs
- Collimation: 1 mm
- Table speed: 1mm/rotation
- Gantry rotation speed: 1 rotation/s

Reconstruction settings

- Reconstruction interval is 0.5 mm.
- Reconstruction kernel: a sharp bone filter is preferred

Multi-Slice CT Scanner

Scan Settings

- Spiral CT
- No gantry tilt
- Tube voltage: 120 kV
- Effective tube current: 90 mAs
- Collimation equals (number of detectors x) smallest detector width
- Feed/rotation is set equal to collimation x 0.7
- Gantry rotation speed is about 0.75 seconds for one rotation

Reconstruction settings

- Reconstruction interval is half detector width (typically: 0.3 mm or 0.5 mm).
- Reconstruction kernel: a sharp bone filter is preferred

Cone-Beam CT Scanner

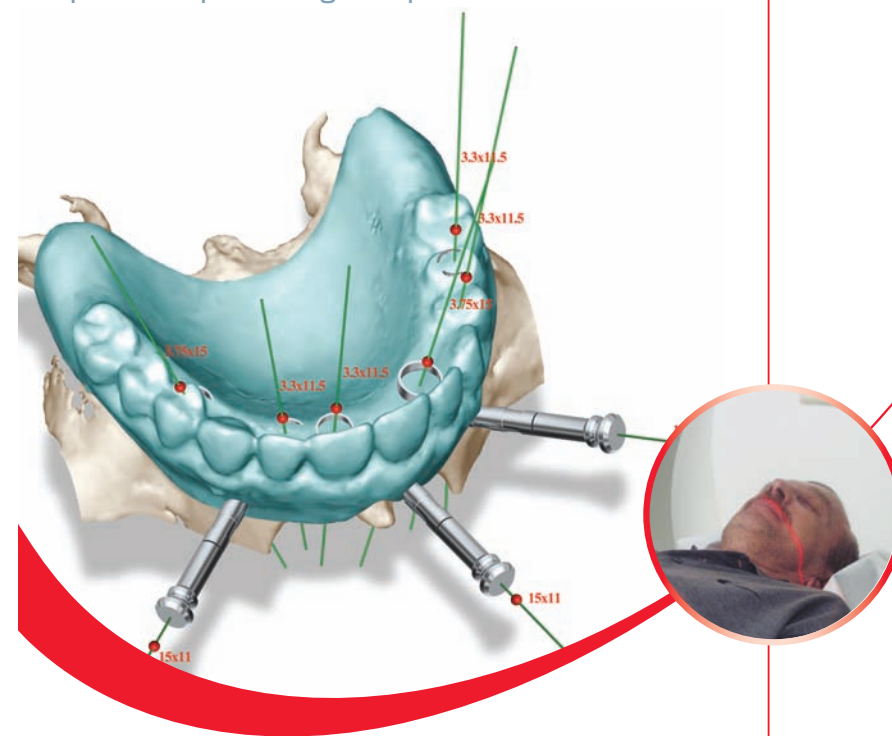
Scan Settings

- The cone-beam CT scanners are dedicated for imaging the skull. Follow the manufacturer's instructions to scan a jaw for oral implant planning. The side of a cubic voxel should be within the range of 0.3 - 0.5 mm.
- During reconstruction, no tilting of the axial slices is allowed.

Radiologist Quick Reference

NobelGuide™

perfect planning for perfect teeth



CT Scanning Guide

Radiologist
Radiology Office
Technicians
And others working with NobelGuide™

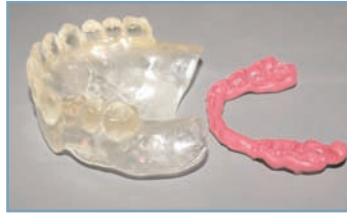

NobelGuide™ Quick Reference Guide for Radiologists

First Scan

The first CT scan in the procedure is a scan of the patient wearing the prepared Radiographic Guide and the Radiographic Index.

1. Confirm that the patient has arrived with the Radiographic Guide (left) and Radiographic Index (right).



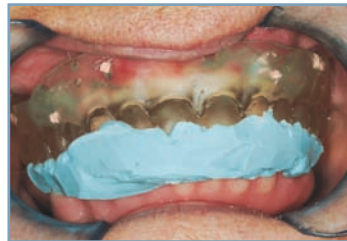2. Verify that there are at least 6 to 8 gutta-percha markers in the Radiographic Guide. They should be round, about 1 to 1.5mm in diameter.



These items are essential to ensure a proper scan. Do not scan the patient if these items are not present or if there are no gutta-percha markers. They must return to the referring dentist and be scanned at a later time.

3. Prepare the equipment. See Generic CT Scan protocols on reverse side. Choose the correct distance between axial slices, with a maximum distance of 0.5mm.

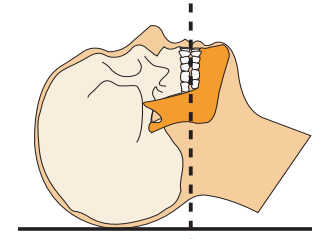
4. Ask the patient to place and align the Radiographic Guide and Radiographic Index as instructed by their doctor. A mirror might be useful for the patient to verify proper positioning.



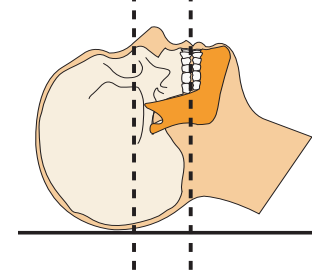
5. Position the patient

Maxilla (upper jaw)

Make sure that the patient is positioned with the occlusal plane and the horizontal laser indicator parallel and coinciding (if the CT scan has a vertical laser indicator, this should be positioned between the two front teeth). No gantry tilt is allowed.

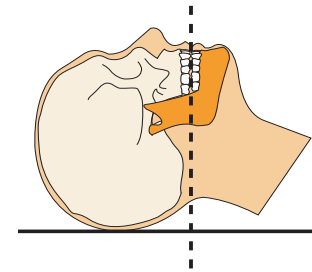


Use a scout image to defined the field of interest. Use axial slices parallel to occlusal plane/hard palate reaching from lower dentition up to cover lower nasal concha.

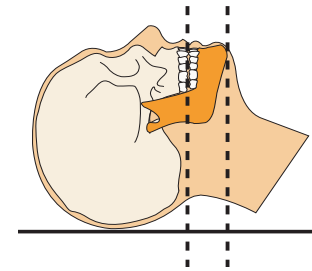


Mandible (lower jaw)

Position the patient so the occlusal plane (dotted line) and the horizontal laser indicator are parallel and coinciding.



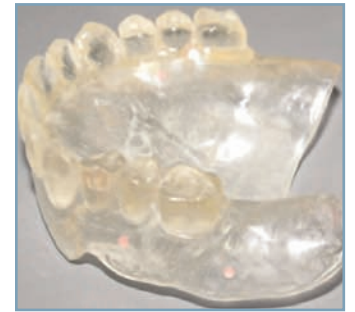Use a scout image to define the field of interest. Use axial slices parallel to occlusal plane/mandibular crest, reaching from upper dentition including entire corpus mandible. No gantry tilt is allowed.



6. Instruct patient to
 - Bite firmly and constantly, but not so hard as to deform the Radiographic Guide
 - Remain still during scanning
 - Do not swallow during scanning
 - Close and relax lips
 - Breathe through nose

Second Scan

1. Scan only the Radiographic Guide. (do not include the Radiographic Index).



2. Retain the same CT settings for the second scan as those used for the first scan, including the same distance of the axial slices.

3. Radiographic Guide should be scanned in a similar position as the patient scan. Position it in the CT scanner, as close to possible as it was located in the patient's mouth during the first scan.



4. Save both files in uncompressed DICOM 3 format, placing each DICOM set into a separate directory.
 - 4a. Either delete scout files or move them into a separate directory.

For complete instructions for using NobelGuide™, please refer to the latest NobelGuide™ Concept Manual